

Diffuse Idiopathic Skeletal Hyperostosis versus Ankylosing Spondylitis: Brief Case Review

Hamidreza Aliabadi, MD[†]
David Biglari, DO[‡]
L. Fernando Gonzalez, MD
Peter Nakaji, MD

Diffuse idiopathic skeletal hyperostosis is sometimes confused with ankylosing spondylitis. We present a case of diffuse idiopathic skeletal hyperostosis and describe its clinical management and the characteristics that may help differentiate this entity from ankylosing spondylitis. Clinicians must be aware of overlapping characteristics between these two disease processes and be able to distinguish between the two because the course of their treatment is considerably different. Key criteria for excluding ankylosing spondylitis and diagnosing diffuse idiopathic skeletal hyperostosis are the absence of sacroiliac fusion, erosion, or sclerosis, which can be determined by obtaining a plain x-ray of the pelvis.

Key Words: ankylosing spondylitis, cervical ankylosis, diffuse idiopathic skeletal hyperostosis

Abbreviations Used: CT, computed tomography; HLA, human leukocyte antigen; MR, magnetic resonance; OPLL, ossification of the posterior longitudinal ligament; OVAL, ossification of the vertebral arch ligaments

Division of Neurological Surgery, Barrow Neurological Institute, St. Joseph's Hospital and Medical Center, Phoenix, Arizona

[†]Division of Neurosurgery, Duke University Medical Center, Durham, North Carolina

[‡]Department of Internal Medicine, Banner Good Samaritan Medical Center, Phoenix, Arizona

Diffuse idiopathic skeletal hyperostosis is an idiopathic form of degenerative arthritis. It is usually characterized by exuberant bony growth along the anterior longitudinal ligament and typically affects males over 60 years of age. Diffuse idiopathic skeletal hyperostosis, previously known as Forestier's disease, is the most common enthesopathy. In 1950 it was originally described by Forestier and Rotes-Querol as a senile ankylosing hyperostosis of the spine.² This condition is associated with extraaxial involvement (i.e., ossification of the nuchal ligament or tendons in the extremities). Patients with this diagnosis can suffer from heel spurs or ligamentous calcification at the elbow or knee.

The other spinal enthesopathies are OPLL and OVAL. Diffuse idiopathic skeletal hyperostosis and ankylosing spondylitis are cervical ankyloses that can be difficult to distinguish from one another. Pathologically, diffuse idiopathic skeletal hyperostosis differs from ankylosing spondylitis. Clinically, however, both are similar. Diffuse idiopathic skeletal hyperostosis has even been referred to as a "senile ankylosing spondylitis."

Ankylosing spondylitis, a chronic inflammatory rheumatic disease, tends to affect relatively young white males. Classically, it is associated with sacroiliac and/or apophyseal fusion or sclerosis. Patients with ankylosing spondylitis are symptomatic and suffer from a myriad of associated conditions such as iritis, uveitis, or ulcerative colitis.

In contrast, patients with diffuse idiopathic skeletal hyperostosis tend to be asymptomatic. However, findings such as dysphagia from esophageal impingement, spinal cord compression, and pe-

ripheral nerve entrapment have been attributed to this form of cervical ankylosis. In practice, most patients are diagnosed after trauma and associated severe neurological deficits, such as quadraparesis or quadriplegia. Even trivial trauma, such as a minor fall or a syncopal episode, may be associated with severe neurological deficits in these individuals.³

Inevitably, the diagnosis of diffuse idiopathic skeletal hyperostosis is confused with ankylosing spondylitis. We present the case of a patient with diffuse idiopathic skeletal hyperostosis and focus on the features that help differentiate it from ankylosing spondylitis.

Illustrative Case

A 69-year-old African-American man with a history of hypertension, diabetes mellitus, and peripheral vascular disease fell down a flight of stairs. He did not lose consciousness. On admission to our Emergency Department, he was significantly quadriparetic and had lost

bowel control. A neurosurgical consultation was obtained.

On examination the patient was oriented to person, place, time, and situation. He opened his eyes spontaneously. His speech was fluent and his repetition was intact. He was able to follow commands. His Glasgow Coma Scale score was 15 (eye opening, 4; verbal response, 5; motor response, 6 following commands). His pupils were equally round and reactive to light. Grossly, his extraocular muscles and cranial nerve functions were intact. However, he had a sensory deficit at the level of the C4 dermatome, below which his sensation to light touch and pin prick was significantly impaired. On motor examination he was found to have a central cord syndrome. His arms were weaker than his legs.

Bilaterally, the strength of his deltoids was 1/5 to 2/5. Bilaterally, the strength of his biceps and triceps was 1/5, and the strength of his grip was 0/5. The cast on his lower right leg precluded a formal motor examination of this limb. How-

ever, strength in his left iliopsoas was 3/5 and 2/5 in his left quadriceps. Both his left plantar strength and dorsiflexion strength were 2/5. A digital rectal examination revealed mildly diminished rectal tone. The patient was started on the methylprednisolone spinal cord injury protocol.

His metabolic profile was as follows: sodium, 138 mEq/L; potassium, 4.5 mEq/L; chloride, 104 mEq/L; bicarbonate, 25 mEq/L; blood-urea-nitrogen level, 21 mg/dL; creatinine, 1.2 mg/dL; and glucose, 231 mg/dL. His white blood cell count was $11 \times 10^3/\text{mL}$. His hemoglobin was 11 gm/dL, and his hematocrit was 33%. His platelet level was $255 \times 10^3/\text{mL}$. His coagulation panel was normal.

CT of the head showed no intracranial hemorrhage, skull fracture, or extraaxial collections. The size and configuration of the ventricles were normal. As interpreted by the radiologist, CT of the cervical, thoracic, and lumbar spine showed "changes consistent with ankylosing spondylitis" but no acute fractures.

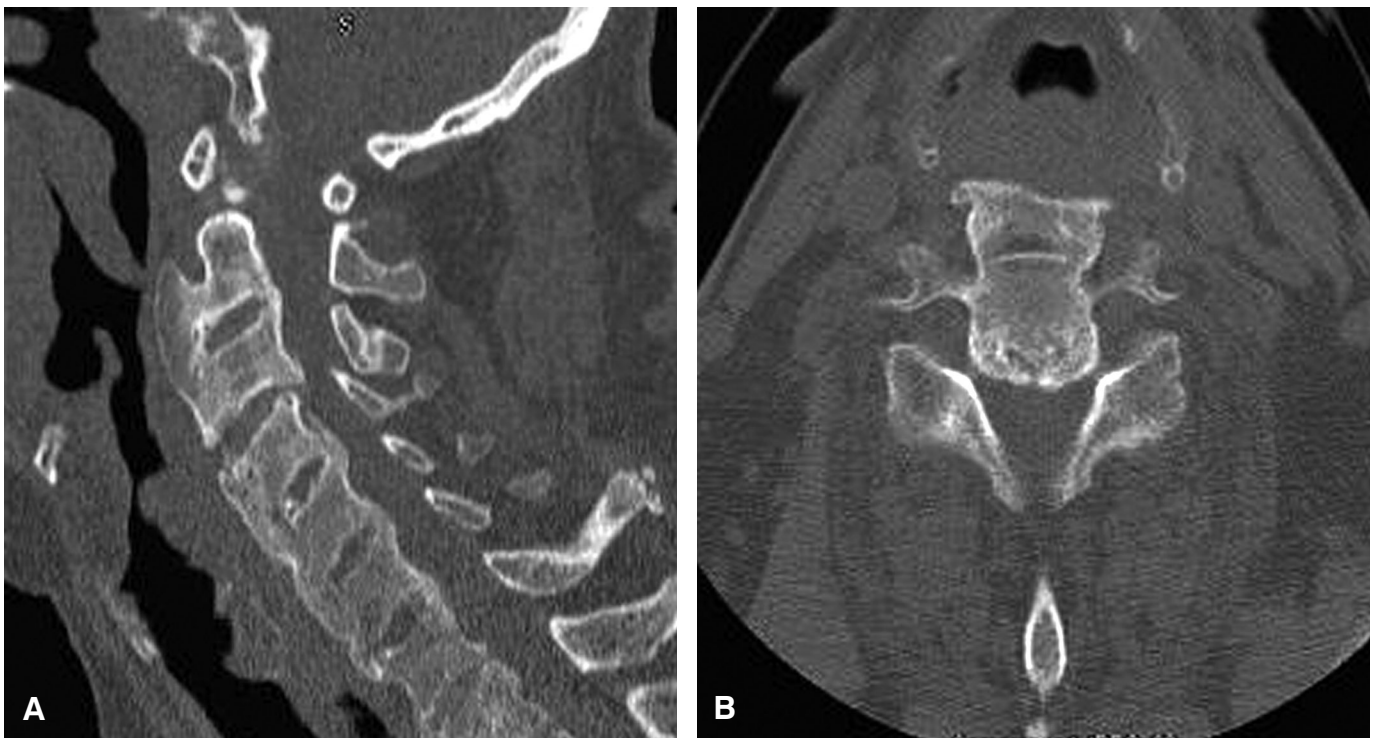

Figure 1. (A) Sagittal and (B) axial CT scans of the cervical spine show either diffuse skeletal hyperostosis or ankylosing spondylitis; both conditions have a similar appearance on CT studies. Ossification of the anterior and posterior longitudinal ligaments is associated with severe osseous ridging along the spine. Hyperostotic changes contribute to the severe stenosis of the spinal canal.

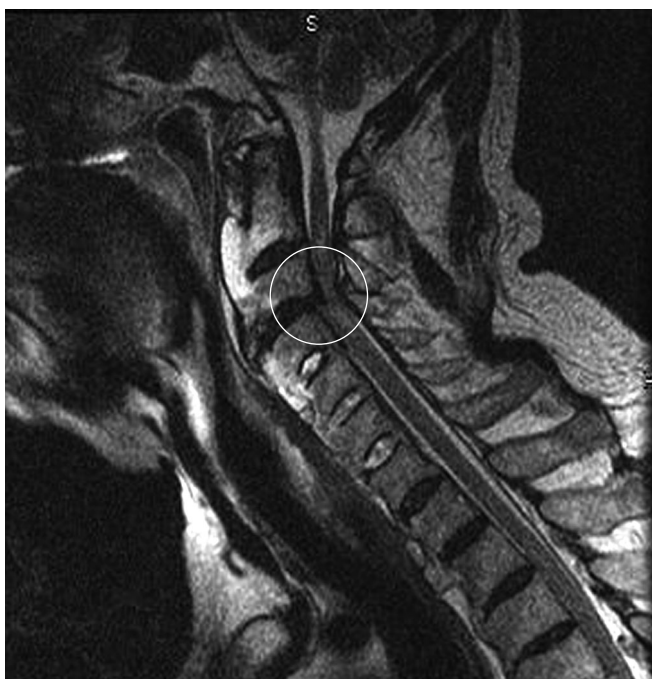

Figure 2. Sagittal T2-weighted MR image of the cervical spine shows a herniated nucleus pulposus at C3-C4 causing a change in the signal intensity of the spinal cord, stenosis of the central canal, and effacement of the ventral cerebrospinal fluid space (*circle*).

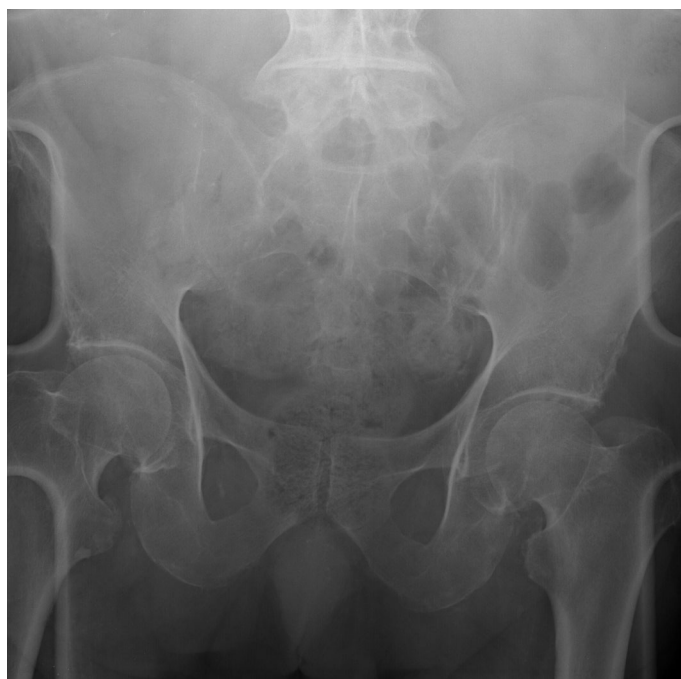

Figure 3. Anteroposterior x-ray of the pelvis shows no evidence of fusion, erosion, or sclerosis of the sacroiliac joint.

Specifically, CT of the cervical spine showed about 3 mm of retrolisthesis of C3 on C4 (Fig. 1). CT of the thoracic spine showed multilevel fusion and satisfactory alignment of the spine. There was evidence of mild-to-moderate degenerative changes associated with osseous ridging. At the midthoracic levels, the central canal was mildly to moderately narrowed. CT of the lumbar spine showed ossification anterior to the vertebral bodies and satisfactory alignment. Small osteophytes were present at L3-4 and L4-5, as was moderate narrowing of the central canal. Calcifications were also present in the descending aorta and proximal iliac arteries. A tiny calcific density involved the right kidney.

MR imaging of the cervical spine showed possible C3 and C4 fractures. Significant T2-weighted changes in the spinal cord at these levels were consistent with edema associated with severe stenosis of the central canal and a herniated nucleus pulposus at C3-4 (Fig. 2). No fusion of the sacroiliac was detected on pelvic radiographs (Fig. 3).

On admission to the intensive care unit for spinal cord trauma, the methylprednisolone protocol was continued. Subsequently, the patient was fixated in a halo brace in neutral cervical position. Based on the findings on his MR images, we performed an anterior cervical discectomy with allograft fusion to decompress the spinal canal at C3-C4 (Fig. 4).

Over the next few days after surgery, the patient developed respiratory distress. Auscultation throughout the lung fields indicated the presence of scattered rhonchi. After several days of aggressive pulmonary toilet and successful weaning from the ventilator, the patient was extubated. Initially, he tolerated the extubation, but the next day he desaturated and became further obtunded. After a respiratory code, he was fiberoptically reintubated emergently. Soon thereafter, an elective tracheostomy was placed.

Over the next few days, the patient's neurological examination fluctuated. Overall, his arms were weaker. However, strength throughout his left lower extremity was slightly improved to 3/5.

Due to the worsening of his upper extremity and to the mild compromise of his cervical spinal canal associated with spinal cord compression on postoperative imaging, we decided to proceed with a decompressive laminectomy of C3 and C4 (Fig. 4). Postoperatively, the patient's strength was improved mildly as follows: bilateral biceps, 1/5 to 2/5; triceps, 3/5; and right and left grips, 1/5 to 2/5, respectively. Compared to his preoperative baseline, his lower extremity motor examination was unchanged, except for slight improvement of his left plantar flexion to 4/5 strength. At this point, the patient was transferred to neurorehabilitation.

Discussion

Diagnostic criteria for diffuse idiopathic skeletal hyperostosis include calcification or ossification of the anterolateral aspect of at least four contiguous vertebral bodies with or without osteophytosis; preservation of disk height without profound degenerative disk dis-

ease; and absence of ankylosing spondylitis, which includes fusion, erosion, or sclerosis of the sacroiliac.^{5,10}

Pathologic features of diffuse idiopathic skeletal hyperostosis include focal and diffuse calcification and ossification of the anterior longitudinal ligament, paraspinal connective tissue, and annulus fibrosis. Other features include degeneration of the peripheral annulus fibrosis fibers; L-, T-, and Y-shaped anterolateral extensions of fibrous tissue; hypervascularity; chronic inflammatory cellular infiltration; and periosteal formation on the anterior surface of the vertebral bodies.⁷

Lower thoracic spine involvement is typical of diffuse idiopathic skeletal hyperostosis, but the rest of the spine can also be affected. Interestingly, the left side of the spine appears to be spared of changes relative to the right side. This observation has been attributed to pulsations from the nearby aorta.

One study described the vertebral involvement of 215 cadaveric spines and 100 patients with diffuse idiopathic skeletal hyperostosis. Radiographic features noted were linear osteogenesis along the anterolateral aspect of the thoracic spine, a bumpy contour, subjacent radiolucency, and irregular and pointed bony excrescences at the superior and inferior vertebral margins in the cervical and lumbar regions.⁷

As mentioned, most patients with diffuse idiopathic skeletal hyperostosis are asymptomatic unless they experience a precipitating trauma. However, some individuals with diffuse idiopathic skeletal hyperostosis complain of back stiffness, dysphagia (presumably because of the exuberant anterior spinal column and anterior longitudinal ligament ossification and osteophytosis impinging on the esophagus), and/or symptoms of myelopathy related to spinal canal compromise such as gait disturbance. Finally, chronic pneumonia has been reported due to bronchial obstruction and compression of the inferior vena cava.

Both diffuse idiopathic skeletal hyperostosis and ankylosing spondylitis are most common in Caucasians. In

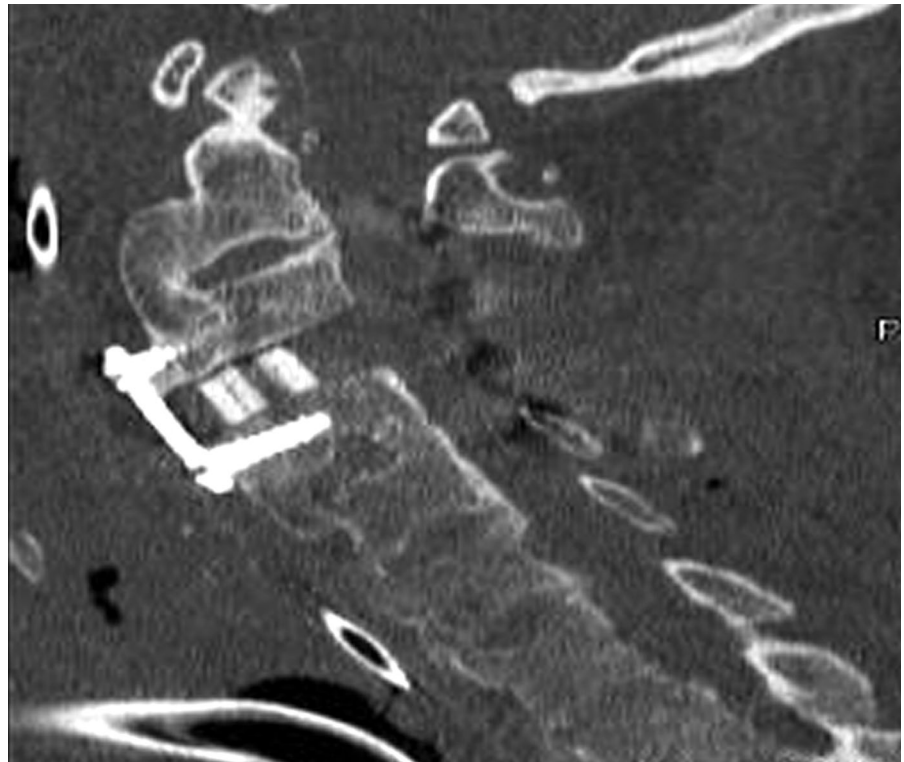


Figure 4. Postoperative sagittal CT scan of the cervical spine shows the decompressed central canal, anterior C3-C4 cervical discectomy with allograft and plate, and posterior decompressive laminectomy at C3 and C4.

African-Americans ankylosing spondylitis is rare while diffuse idiopathic skeletal hyperostosis is common. Clinicians must be aware that the features of these two disease processes overlap and must be able to differentiate the two conditions because the course of their treatment is considerably different. For example, the treatment of ankylosing spondylitis may include the use of indomethacin and other nonsteroidal anti-inflammatory drugs, immunosuppressive treatment with monoclonal antibody therapy, and physical therapy.¹

The association between HLA-B27 and ankylosing spondylitis is strong.⁴ Surprisingly, bacteria appear to play a role in the development of this disease.⁸ In contrast, diffuse idiopathic skeletal hyperostosis usually occurs in middle-aged and older males and, as mentioned, is more common in African-Americans than ankylosing spondylitis. There is no ankylosis of the sacroiliac or apophyseal joints in patients with diffuse idiopathic skeletal hyperostosis (as evidenced by the

normal pelvic radiograph in our patient). Finally, no strong genetic link has been identified in patients with diffuse idiopathic skeletal hyperostosis as has been found in patients with ankylosing spondylitis.⁶

The pathologic cause of diffuse idiopathic skeletal hyperostosis remains elusive. No genetic component appears to be present in most cases of chondrocalcinosis. However, a considerable number of cases seem to have a genetic predisposition for the condition, and an autosomal dominant pattern is evident. Linkage studies have shown the presence of a single locus in most cases of chondrocalcinosis. Based on the cases studied to establish a genetic background for disorders such as diffuse idiopathic skeletal hyperostosis or OPLL, chromosomes 5 and 8 appear to be most prominently involved, and two particular regions are involved on each chromosome. In one study, Tsukahara et al. showed a significant association between diffuse idiopathic skeletal hyperostosis in Japanese

patients and COL6A1 compared to Czech patients with the disease. Based on previous genomic linkage and linkage disequilibrium studies by the same authors and others, individuals with COL6A1 have been shown to be significantly susceptible to OPLL.⁹

Conclusion

Inevitably, the diagnosis of diffuse idiopathic skeletal hyperostosis is confused with ankylosing spondylitis. However, as described, identifying certain signs and symptoms leads to an accurate diagnosis. Diffuse idiopathic skeletal hyperostosis and ankylosing spondylitis are clinical entities with similar findings but different treatments. Accurate differentiation of these two conditions is vital to ensure that patients with severe cer-

vical ankylosis receive the appropriate clinical management.

References

1. Braun J, Brandt J, Listing J, et al: Treatment of active ankylosing spondylitis with infliximab: a randomised controlled multicentre trial. **Lancet** **359**:1187-1193, 2002
2. Forestier J, Rotes-Querol J: Senile ankylosing hyperostosis of the spine. **Ann Rheum Dis** **9**:321-330, 1950
3. Gibson T, Schumacher HR: Ankylosing hyperostosis with cervical spinal cord compression. **Rheumatol Rehabil** **15**:67-70, 1976
4. Khan MA: Update: The twenty subtypes of HLA-B27. **Curr Opin Rheumatol** **12**:235-238, 2000
5. Mazieres B, Rovinsky J: Non-inflammatory enthesopathies of the spine: A diagnostic approach. **Baillieres Best Pract Res Clin Rheumatol** **14**:201-217, 2000
6. McCafferty RR, Harrison MJ, Tamas LB, et al: Ossification of the anterior longitudinal ligament and Forestier's disease: an analysis of seven cases. **J Neurosurg** **83**:13-17, 1995
7. Resnick D, Niwayama G: Radiographic and pathologic features of spinal involvement in diffuse idiopathic skeletal hyperostosis (DISH). **Radiology** **119**:559-568, 1976
8. Sieper J, Braun J: Pathogenesis of spondylarthropathies. Persistent bacterial antigen, autoimmunity, or both? **Arthritis Rheum** **38**:1547-1554, 1995
9. Tsukahara S, Miyazawa N, Akagawa H, et al: COL6A1, the candidate gene for ossification of the posterior longitudinal ligament, is associated with diffuse idiopathic skeletal hyperostosis in Japanese. **Spine** **30**:2321-2324, 2005
10. Utsinger PD: Diffuse skeletal hyperostosis (DISH, ankylosing hyperostosis), in Moskowitz RW, Howell DS, Goldberg VM, et al (eds): *Osteoarthritis. Diagnosis and Management*. Philadelphia: Saunders, 1984, pp 225-233