

# Thoracoscopy: A Minimally Invasive Approach to the Anterior Thoracic Spine

---

Justin C. Clark, MD  
Mark E. Oppenlander, MD  
Curtis A. Dickman, MD

---

*Anterior approaches to the thoracic spine are among the most challenging treatment strategies for spine surgeons. An anterior approach is necessary for many types of thoracic spine pathology, in order to safely remove the lesion without causing injury to the spinal cord. Traditionally, the anterior thoracic spine is approached via an open thoracotomy; however, this type of approach is associated with an inherently high rate of morbidity. In an attempt to provide patients with a less morbid surgical treatment for these challenging lesions, the senior author, Dr. Curtis Dickman, spent the early part of his career developing less invasive surgical approaches to the anterior thoracic spine using endoscopic techniques (i.e., thoracoscopy). The benefits of thoracoscopy are many, including a lower rate of morbidity due to less intraoperative blood loss, improved cosmetic results due to smaller incisions, and potentially decreased medical costs as a result of shorter hospital stays and less postoperative pain. This article reviews the types of spinal pathology that are well suited to being treated by thoracoscopy.*

**Key Words:** endoscopic resection, schwannoma, sympathectomy, thoracic spine, thoracoscopic discectomy, thoracoscopy

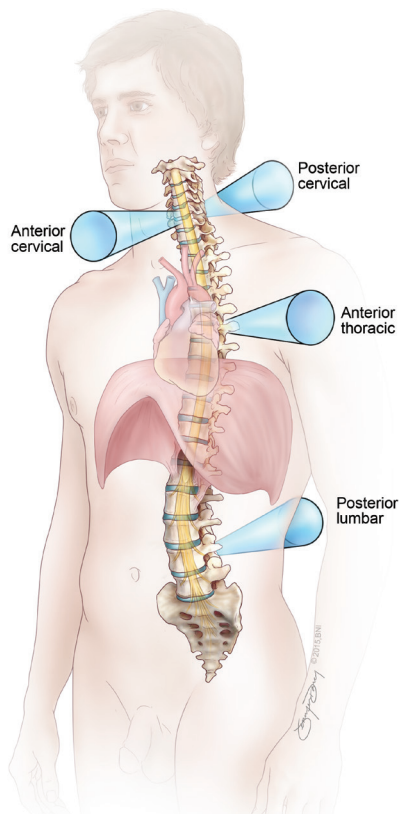
**Abbreviations Used:** HTD, herniated thoracic discs; MIS, minimally invasive surgery

---

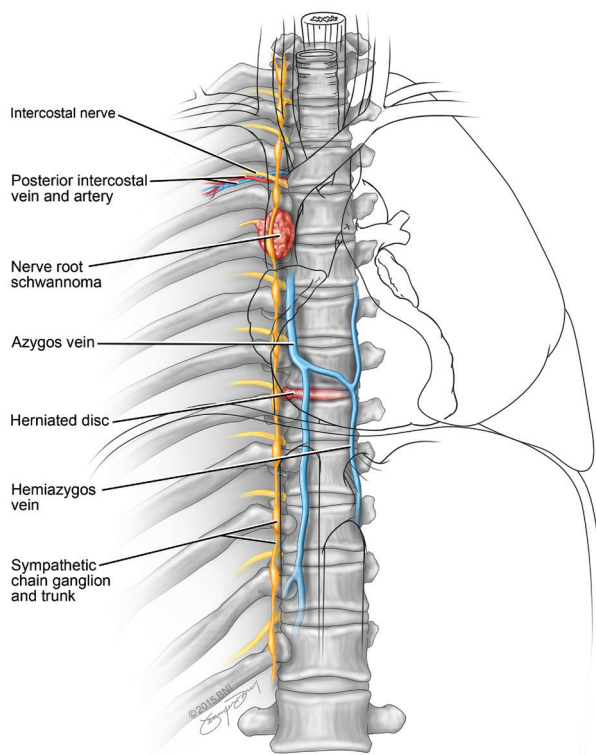
*Division of Neurological Surgery, Barrow Neurological Institute, St. Joseph's Hospital and Medical Center, Phoenix, Arizona*

Major efforts are being made across all surgical specialties to adopt and improve minimally invasive surgical (MIS) techniques. The main goal of minimally invasive surgery is a surgical outcome that is equivalent or superior to traditional open surgical techniques, but with smaller incisions and less soft tissue disruption than traditional open surgery. The theoretical benefits of using MIS techniques are improved wound healing and wound aesthetics, decreased postoperative pain, and improved cost containment through reduced hospital stays. However, MIS techniques often require surgeons to use endoscopic instruments and to rely on limited anatomical landmarks. In addition, these procedures require advanced operative skills that many seasoned surgeons did not learn during residency. Although these skills can be learned, there is usually an initial learning curve awaiting the surgeons as they begin adopting these skills. Nevertheless, the requests from patients to be treated with MIS techniques, as well as the promise for improved patient outcomes and cost containment, have been the persistent impetus driving surgeons to develop and incorporate MIS techniques into their daily practices.

Spine surgeons have long been proponents at least of the concepts, if not the adoption, of MIS techniques. The challenge with all MIS techniques in the spine is that the surgeon must maintain a high level of manual dexterity around areas that are very sensitive to manipulation and deformation (i.e., the spinal cord) while decreasing the size of the corridor through which the sur-



**Figure 1.** Illustration of various approaches that can be used in minimally invasive spine surgery (MIS). Due to the inherently long skin-to-spine distance through the thoracic cavity and the low tolerance of the spinal cord to manual deformation, anterior approaches to thoracic spine are more challenging when using MIS techniques than with MIS for other segments of the spine.



**Figure 2.** The right-sided thoracoscopic approach to the spine allows the surgeon access to many important structures, including segmental nerves, veins, and arteries, and the thoracic sympathetic chain, as well as any pathologies associated with these structures. Care must be taken not to damage the lungs, heart, great vessels, diaphragm, or esophagus (*shown in outline*) during this approach.

geon operates. The cervical and lumbar spines both lend themselves well to MIS techniques. The cervical spine is conducive to MIS techniques because of the short distance from skin to spine compared to the anterior thoracic and lumbar spine. This short distance allows the surgeon's hands to get very close to the spinal pathology through the MIS technique, which maintains the high level of manual dexterity that the surgeon would normally have during a normal open surgical case. The lumbar spine is well suited for MIS techniques because, on most patients, the spinal cord stops at the thoracolumbar junction, which allows the surgeon to operate around the more forgiving cauda equina. Unlike the spinal cord and conus medullaris, the cauda equina can be significantly manipulated during surgery without causing permanent

neurological deficits. The anterior thoracic spine, however, is more challenging to approach by MIS techniques because of its long skin-to-spine distance (i.e., intrathoracic cavity) and the low tolerance of the spinal cord to manual deformation (Fig. 1).

In an attempt to overcome the anatomical and physiological barriers to developing a minimally invasive approach to the anterior thoracic spine, the senior author (C.A.D.) has pioneered the development of thoracoscopy as an endoscopic MIS technique for treating conditions of the anterior thoracic spine, and he has shared his expertise with other surgeons through hands-on continuing medical education workshops. The fruits of this labor are the thoracoscopic techniques that are in use around the country and around the world today.

## Anatomy

When a surgeon is evaluating a patient for a thoracoscopic approach, it is important to determine which side is optimal for the surgical approach. There exist significant anatomical differences between the right and left chest cavities. If all else is equal, it is generally felt that the thoracic spine is more easily approached through the right chest wall than the left chest wall, because the surgical corridor through the right chest does not require the surgeon to have to deal with the heart or the aorta, which both predominantly reside in the left chest. However, many important anatomical structures are encountered through a right-sided approach (Fig. 2). After the right lung is selectively deflated by the anesthesiologist, the surgeon is able to view the anterolateral spinal column, which is crossed

at each vertebral level by the segmental veins and arteries. As the thoracic nerve roots exit their neural foramina, they join with the segmental vessels at each level to course along the caudal surface of their respective ribs. In doing so, this neurovascular bundle runs superficially (in relation to the skin) to the thoracic sympathetic chain, which can be seen running along the rib heads in parallel with the spinal column. In the cranial aspect of the chest cavity, care must be taken not to damage the vagus nerve or esophagus; in this region, they can be seen lying just beneath the parietal pleura.

Although many of the anatomical structures are duplicated in the right and left chest cavities, there are some notable exceptions between these two areas. The left chest is occupied to a significant extent by the heart, which can make operating in this area more cumbersome. On the left, the anterior aspect of the thoracic spine is also covered by the thoracic segment of the aorta. This large vascular structure must often be mobilized from the thoracic spine to allow access to the vertebral bodies. More importantly, great attention must be paid to any hardware that is placed on the thoracic spine in proximity to the aorta, as there is a very real potential for the hardware to erode through the aorta if there is contact between them. For all these reasons, it is preferable for the surgeon to access the right chest wall for thoracoscopic procedures; however, the need to access the pathology through the left chest is not a contraindication for the thoracoscopic approach.

## Surgical Technique

The patient is brought to the operating room and placed in the supine position on the operating table. The induction of general anesthesia occurs in the usual fashion. The patient is intubated by the anesthesiologist using a dual lumen endotracheal tube. The dual lumen endotracheal tube allows for selective deflation of the lung during the case, which facilitates visualization of

the spinal anatomy during the surgery. If the patient is being treated for a lesion causing spinal cord compression, care is taken by the anesthesiologist to avoid episodes of hypotension by maintaining the patient's mean arterial pressure higher than 60 mm Hg at all times. Somatosensory and motor evoked potentials are monitored throughout the case. After invasive vascular lines are placed for real-time cardiovascular monitoring and delivery of high-volume fluids, the patient is then placed in the lateral decubitus position. The patient is positioned in the left lateral decubitus position for a right-sided approach and in the right lateral decubitus position for a left-sided approach. The ipsilateral arm is placed in an airplane sling and abducted away from the chest wall so it is out of the way during surgery. At this point, the patient's chest is prepped and draped in a sterile fashion, and the operating room is set up in the usual fashion (Fig. 3). The chest wall is then accessed near the midaxillary line via soft endoscopic portals in order to pass surgical instruments into the chest wall (Fig. 4). The endoscope is then introduced into the thoracic cavity, followed by the endoscopic tools, and the surgeon is then able to address the patient's specific pathology.

The indications for thoracoscopic surgery range from relatively simple procedures, such as thoracic sympathectomies, to more complex procedures, such as tumor removal, discectomy, and corpectomies with placement of instrumentation. In the following sections, we will present thoracic pathologies that are routinely treated via thoracoscopic techniques at Barrow Neurological Institute.

## Thoracoscopic Sympathectomy

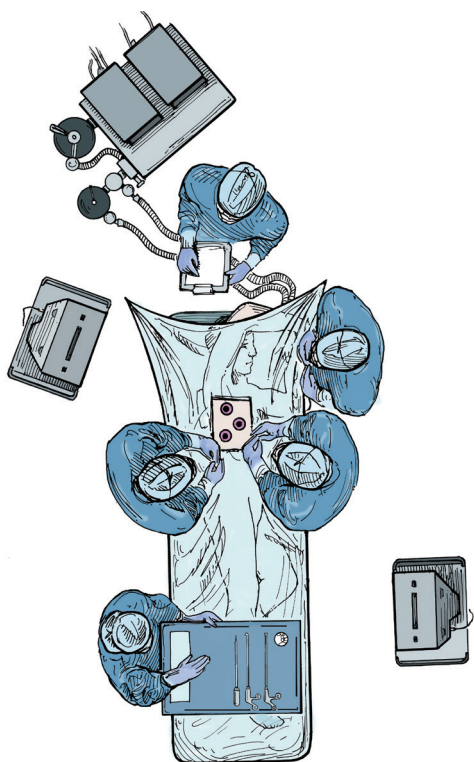
Hyperhidrosis is a clinical condition that causes patients to sweat profusely and unpredictably. Patients with this condition often sweat even when temperatures are cool and they are resting. The cause of hyperhidrosis is excessive

sympathetic output through the sympathetic chain ganglia (Fig. 2) to the sweat glands of the affected body part, usually the hands, feet, face, or axillae. When the condition affects the palms of the hands, the condition is called palmar hyperhidrosis. When the soles of the feet and armpits are involved, the condition is called plantar and axillary hyperhidrosis, respectively. For many patients, this disease is debilitating, as it negatively affects many aspects of their personal and professional lives. Patients with palmar hyperhidrosis often sweat so profusely that sweat can be seen dripping from their hands, causing them to soak papers being held in their hands, as well as making them self-conscious about shaking hands with others.

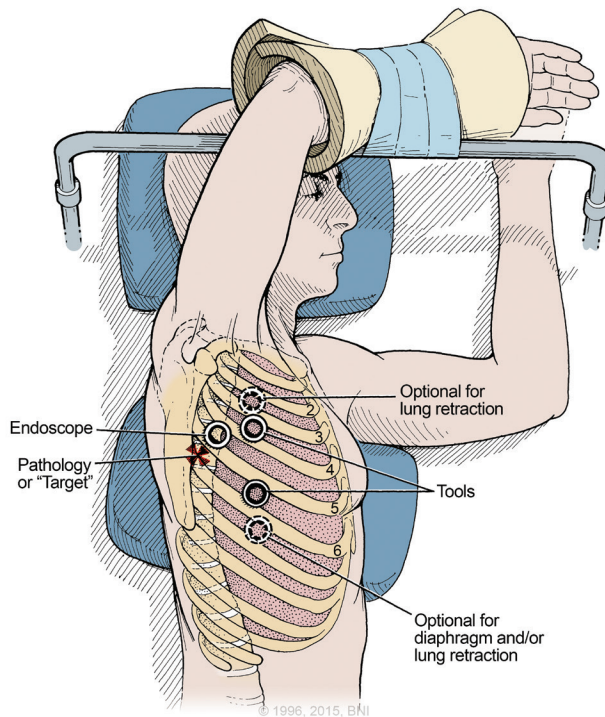
Several medical treatments are available for this condition, including the use of topical antiperspirants, oral medications such as anticholinergic drugs and beta-blockers, and the use of iontophoresis and Botox (botulinum toxin type A). It is important to rule out other causes of hyperhidrosis, such as endocrinopathies, before initiating treatment for presumed primary hyperhidrosis. Patients who fail these treatments are often referred for surgical treatment in the form of sympathectomy. A surgical sympathectomy involves cutting the sympathetic ganglia of the upper thoracic spine in order to decrease the sympathetic output to specific parts of the body (Fig. 2). Traditionally, sympathectomy has been offered via an open surgical approach. The open approach involves a large incision being made in the patient's chest to surgically access the upper thoracic spine. At Barrow Neurological Institute, neurosurgeons are able to offer a minimally invasive approach for treating hyperhidrosis. Specifically, they provide patients with a thoracoscopic approach for creating the sympathetic lesion.

## Illustrative case 1

A 26-year-old man was referred to the senior author (C.A.D.) because of excessive sweating of the palms of his hands and the soles of his feet. His symp-



**Figure 3.** The operating room setup, with the surgeons standing on the patient’s ventral side. The anesthesiologist is positioned near the patient’s head, which allows easy access to the airway during the case. In this illustration, two surgical scrub technicians pass instruments to the surgeons during the case from their positions on the patient’s dorsal side. From Dickman CA, Rosenthal DJ: *Operating room setup and patient positioning*. In Dickman CA, Rosenthal D, Perrin N (eds): *Thoracoscopic spine surgery*. New York: Thieme, 1999, pp. 95-106. Modified with permission from Thieme.



**Figure 4.** Soft endoscopic portals are positioned near the midaxillary line, allowing placement of surgical instruments through the chest wall.

toms were severe and had been present since early childhood. He reported that his sweating had been constant and profuse, with sweat often dripping from his hands. The excessive sweating interfered with both his personal and professional life, and it was a constant source of anxiety for him. He had failed to respond to extensive nonsurgical measures. His physical examination and laboratory results were all negative for any form of endocrinopathy or other abnormalities. He was diagnosed with primary palmar and plantar hyperhidrosis and was offered bilateral thoracoscopic sympathectomies as treatment. The patient consented and underwent surgery successfully (Video 1). In the recovery room, the patient was pleased to report that his hands “felt completely dry.” He

was discharged home from the hospital later that same day, a few hours after surgery. His results have remained stable at a 4-week follow-up conducted via telephone.

The outcomes of patients treated by the senior author (C.A.D.) for primary hyperhidrosis have been published previously.<sup>11,12</sup> In his largest series, the clinical outcomes of 322 patients were analyzed.<sup>12</sup> These patients presented with hyperhidrosis of the hands (13.4%), axillae (4.0%), or craniofacial region (1.2%), or some combination of these three (81.4%). The results of sympathectomy were excellent, with 99.7% of patients with palmar hyperhidrosis experiencing complete resolution of their symptoms. The results of sympathectomy for axillary and craniofacial

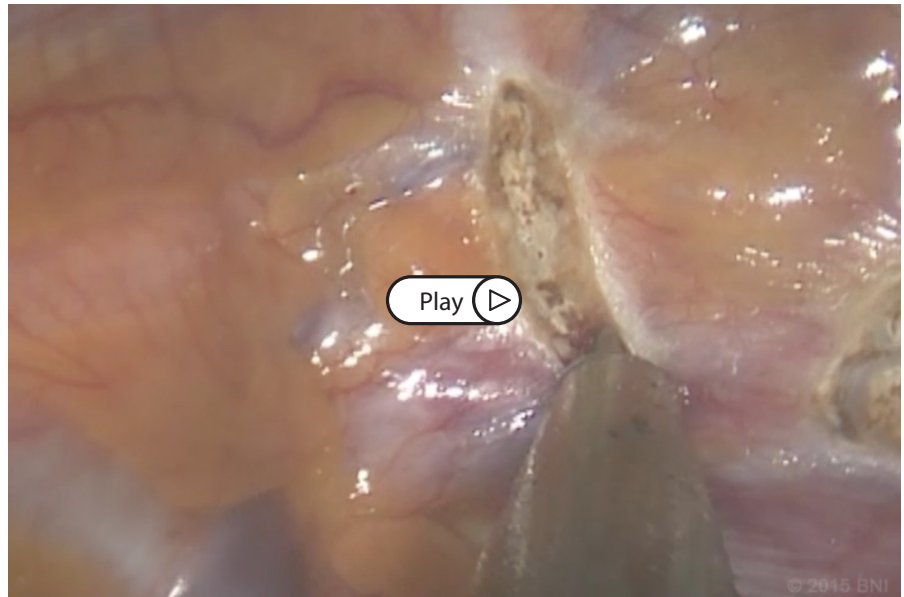
hyperhidrosis were also encouraging, with symptom resolution in 89.1% of patients and improvement in 100%. The most common complication associated with this surgical treatment was Horner’s syndrome, and the most common side effect was compensatory sweating. When the technique was changed from excision of the sympathetic chain to in situ transection of the sympathetic chain at T2–3, the complication of Horner’s syndrome was significantly reduced from 5% to 0.9% overall. The utility of this operation can be seen by the fact that 98.1% of patients who underwent treatment reported satisfaction with their results and indicated a willingness to undergo the procedure again.<sup>12</sup> Sympathectomy is effective not only in adults, but also in adolescents.<sup>11</sup>

## Intrathoracic tumors

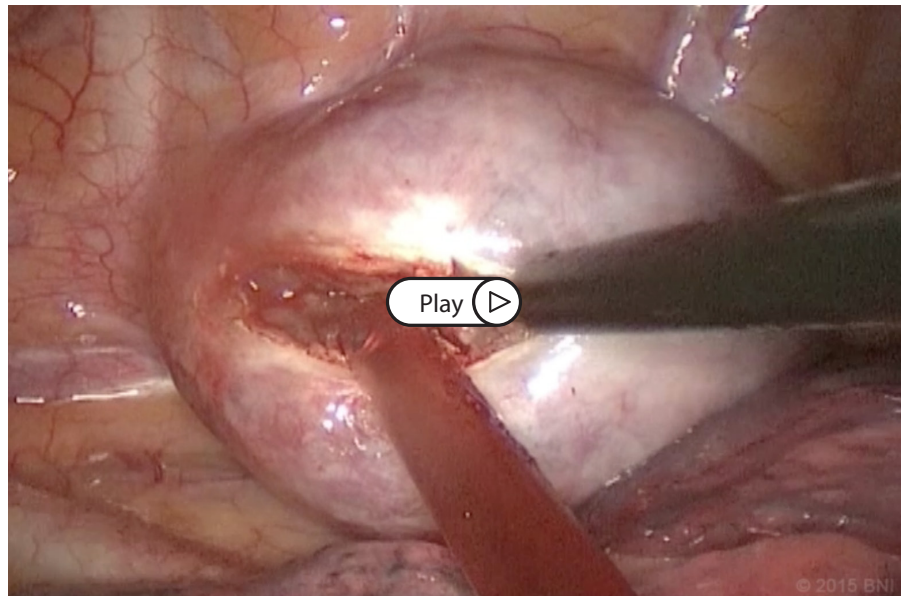
The evolution of MIS approaches to the anterior thoracic spine has broadened the role of thoracoscopy to the treatment of a variety of intrathoracic tumors, especially paraspinal neurogenic tumors. Despite being relatively uncommon in the body overall, paraspinal neurogenic tumors account for 75% of posterior mediastinal masses.<sup>9</sup> They cause pain, limit pulmonary function, and cause Horner's syndrome. For these reasons, intrathoracic tumors should undergo biopsy and, if possible, surgical resection. Thoracoscopic surgery is an excellent option for many patients with intrathoracic tumors.<sup>6</sup>

Paraspinal neurogenic tumors emanate from the neural structures surrounding the spine, specifically the sympathetic chain ganglia or the exiting nerve roots (Fig. 2). Resection of these lesions is not without risk. Undue tension on, or trauma to, the upper thoracic sympathetic chain can lead to Horner's syndrome. The same manipulation of a tumor attached to a nerve root can cause a traumatic cerebrospinal fluid leak, or even a spinal cord injury. Because of these risks, resection of these lesions must be undertaken with extreme care.

Despite the sensitivity of this area to surgical manipulation, the experience at Barrow Neurological Institute demonstrates that many of these tumors can be well managed via thoracoscopic resection. During a 14-year period, 26 patients underwent thoracoscopic resection of paraspinal neurogenic tumors. Most (57%) of these patients were found to have schwannomas. Gross total resection was achieved in 25 of the 26 patients. The remaining patient underwent biopsy followed by radiation therapy. Only 1 patient suffered permanent treatment-related morbidity in the form of mild Horner's syndrome. There were no recurrences, with a mean imaging follow-up of 54 months.<sup>8</sup> These results demonstrate that thoracoscopic surgery is a safe and effective technique for treating intrathoracic paraspinal tumors, and that this MIS technique does not put patients at



**Video 1.** The thoracoscopic sympathectomy demonstrates the low morbidity associated with the thoracoscopic approach. Because it is a short surgery that requires only 2 endoscopic portals, patients are usually discharged home the same day as surgery, with complete resolution of their hyperhidrosis symptoms. <https://www.barrowneuro.org/Thoracoscopy1>



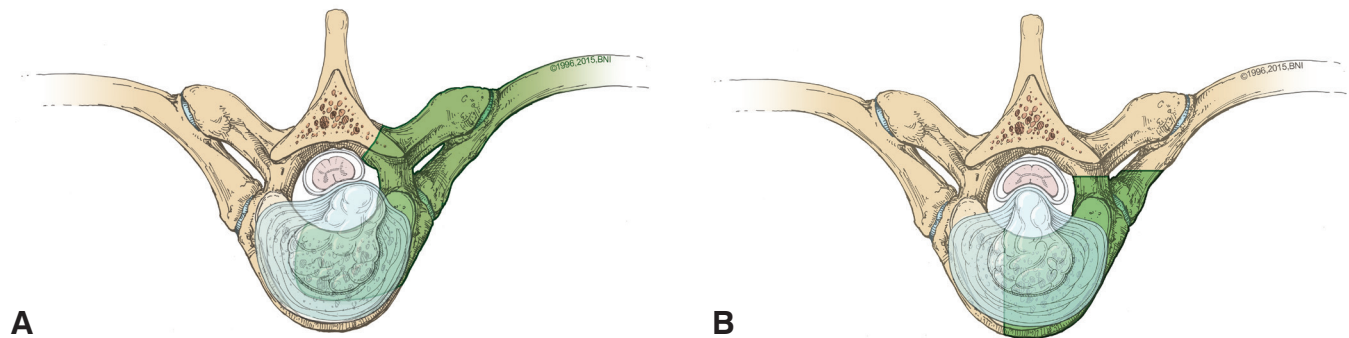
**Video 2.** As demonstrated by this resection of a thoracic schwannoma, the thoracoscopic technique can provide the surgeon with substantial dexterity and the subtle tactile feedback required to remove these lesions without causing damage to surrounding neurovascular structures. <https://www.barrowneuro.org/Thoracoscopy2>

increased risk for complications.

### Illustrative case 2

A 32-year-old, otherwise healthy man presented to the emergency department after episodes of pleuritic chest pain and shortness of breath.

Imaging demonstrated an enhancing paraspinal lesion in the upper thoracic spine consistent with a schwannoma. He was offered thoracoscopic resection of the lesion, to which he agreed (Video 2). The operation went well and he awoke at his neurological baseline.



**Figure 5.** (A) Laterally located herniated thoracic discs (HTDs) are most appropriately approached via posterolateral surgical approaches, such as costotransversectomy. (B) Centrally located HTDs must be approached via anterolateral approaches, such as thoracoscopy or open thoracotomy.

He was discharged home without incident on postoperative day 2.

## Herniated Thoracic Discs

Although degenerative disc disease affects all segments of the spine, the thoracic spine has a lower incidence of degenerative disc disease than the cervical or lumbar spine because of its relative rigidity. Herniated thoracic discs (HTD) have an estimated prevalence of 11.1% to 37%, as diagnosed by computed tomographic myelography or magnetic resonance imaging;<sup>2,13,14</sup> however, clinically symptomatic HTDs are believed to be exceedingly rare.<sup>3</sup> Nevertheless, the outcomes of patients with untreated symptomatic HTDs are extremely poor; therefore, patients presenting with symptomatic HTDs require surgical intervention for decompression. HTDs can be located either centrally or laterally. In 1960, two separate reports found that decompressive laminectomy for the treatment of clinically symptomatic HTDs was associated with unacceptably high complication rates.<sup>1,5</sup> Laterally located HTDs can be approached via a posterolateral surgical approach, such as costotransversectomy (Fig. 5A). However, centrally located HTDs must be approached via an anterolateral approach, such as open thoracotomy or thoracoscopy (Fig. 5B). The benefits of thoracoscopy over traditional open thoracotomy for the treatment of symptomatic centrally lo-

cated HTDs include the decreased incidence of postoperative pain, intercostal neuralgia, pulmonary complications, shoulder girdle dysfunction, and chronic pain syndromes.<sup>4,7</sup> However, it is important to note that thoracoscopy does have inherent limitations that make it a suboptimal approach for certain HTDs. On the basis of the extensive experience of the senior author (C.A.D.), we believe that the indications for thoracoscopic resection of symptomatic HTDs include small (occupying <40% of the spinal canal), centrally located discs in patients who were not morbidly obese and who had a favorable chest anatomy and a T4–T11 location.

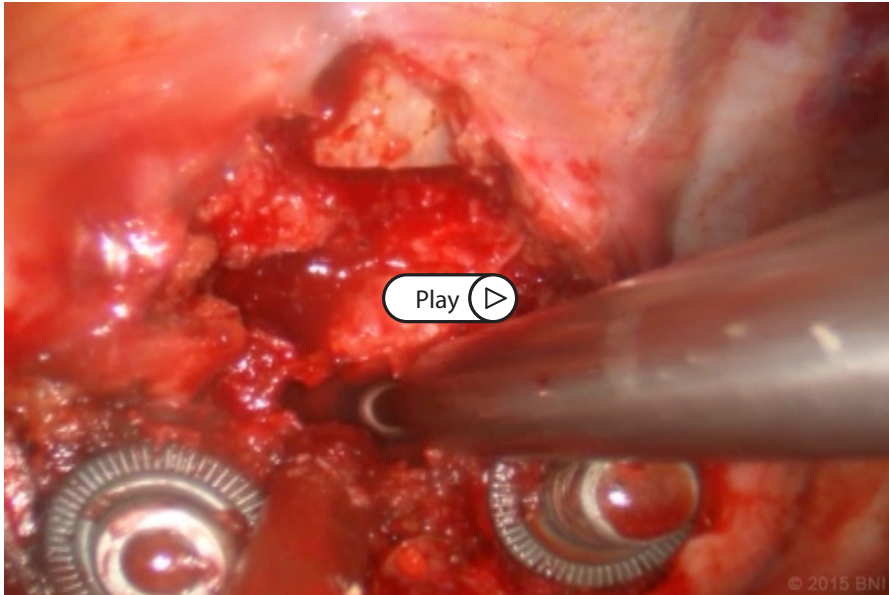
The results of this treatment paradigm were reported previously by Wait et al. in a series of 121 patients who underwent 125 thoracoscopic procedures for 139 HTDs.<sup>10</sup> The most common presentation was radiculopathy, followed by myelopathy. Compared to an unmatched cohort of 39 patients who underwent open thoracotomy for resection of HTDs, patients who underwent thoracoscopic resection had a shorter mean length of hospital stay (4.9 days vs. 8.6 days), shorter mean chest tube duration (3.4 days vs. 4.6 days), and lower mean estimated blood loss (311 mL vs. 1,440 mL). At last follow-up, the patients also reported a lower incidence of intercostal neuralgia (5.8% vs. 23.1%).

### Illustrative case 3

A 67-year-old woman with a history of osteoporosis was referred to our clin-

ic for long-standing left-sided thoracic radicular pain. Three years previously, she suffered an episode in which she became acutely weak on the left side of her body from the waist down. This episode was spontaneous and was not accompanied by pain. At that time, she was taken to an outside hospital where she was told she had “compression between T7 and T8.” She was treated nonsurgically and within 4 days she began to recover movement in her leg. She was eventually discharged and, after undergoing physical therapy, was able to ambulate without assistance 3 months later. Nevertheless, at the time of examination in our clinic, she reported that she continued to have left foot drop, “atrophy” of her left leg, and sensory deficits of the left lower extremity.

Magnetic resonance imaging of her spine demonstrated an HTD at the T7–8 level, which was creating persistent compression of the spinal cord. Given her dramatic history of acute monoplegia of the left leg, as well as her persistent neurological deficits, we recommended that she undergo surgical resection of the HTD. Because the disk was centrally located, she required an anterior thoracic approach. The imaging characteristics of the HTD demonstrated that it would be favorable for thoracoscopy; consequently, she was offered a right-sided thoracoscopic resection of the HTD. Her diagnosis of osteoporosis put her at increased risk for progressive kyphotic deformity, so we recommended that she undergo simul-



**Video 3.** Use of the thoracoscopic technique to treat herniated thoracic discs allows patients to benefit from the same extent of spinal decompression as with the open technique, but without exposing them to the same degree of perioperative morbidity that is associated with open transthoracic approaches. <https://www.barrowneuro.org/Thoracoscopy3>

taneous fixation and fusion at the time of surgery. She consented to this course of action and the operation went well (Video 3). At her three-month follow-up, her strength had returned to normal and she had made an excellent recovery. In addition, the patient expressed great satisfaction with her surgical outcome.

## Conclusions

Thoracoscopy is a safe, effective surgical technique that effectively treats many types of pathology affecting the thoracic spine. Patients treated with thoracoscopic techniques can expect reduced approach-related soft-tissue morbidity and an increased rate of post-surgical recovery.

## References

1. Arseni C, Nash F: Thoracic intervertebral disc protrusion: a clinical study. **J Neurosurg** 17:418-430, 1960

2. Awwad EE, Martin DS, Smith KR, Jr., Baker BK: Asymptomatic versus symptomatic herniated thoracic discs: their frequency and characteristics as detected by computed tomography after myelography. **Neurosurgery** 28:180-186, 1991
3. Carson J, Gumpert J, Jefferson A: Diagnosis and treatment of thoracic intervertebral disc protrusions. **J Neurol Neurosurg Psychiatry** 34:68-77, 1971
4. Ferson PF, Landreneau RJ, Dowling RD, Hazelrigg SR, Ritter P, Nunchuck S, et al: Comparison of open versus thoracoscopic lung biopsy for diffuse infiltrative pulmonary disease. **J Thorac Cardiovasc Surg** 106:194-199, 1993
5. Hulme A: The surgical approach to thoracic intervertebral disc protrusions. **J Neurol Neurosurg Psychiatry** 23:133-137, 1960
6. Lacreuse I, Valla JS, de Lagaussie P, Varlet F, Helouly Y, Temporal G, et al: Thoracoscopic resection of neurogenic tumors in children. **J Pediatr Surg** 42:1725-1728, 2007
7. Landreneau RJ, Hazelrigg SR, Mack MJ, Dowling RD, Burke D, Gavlick J, et al: Postoperative pain-related morbidity: video-assisted thoracic surgery versus thoracotomy. **Ann Thorac Surg** 56:1285-1289, 1993
8. Ponce FA, Killory BD, Wait SD, Theodore N, Dickman CA: Endoscopic resection of intrathoracic tumors: experience with and long-term results for 26 patients. **J Neurosurg Spine** 14:377-381, 2011
9. Shields TW, Reynolds M: Neurogenic tumors of the thorax. **Surg Clin North Am** 68:645-668, 1988
10. Wait SD, Fox DJ, Jr., Kenny KJ, Dickman CA: Thoracoscopic resection of symptomatic herniated thoracic discs: clinical results in 121 patients. **Spine (Phila Pa 1976)** 37:35-40, 2012
11. Wait SD, Killory BD, Lekovic GP, Dickman CA: Biportal thoracoscopic sympathectomy for palmar hyperhidrosis in adolescents. **J Neurosurg Pediatr** 6:183-187, 2010
12. Wait SD, Killory BD, Lekovic GP, Ponce FA, Kenny KJ, Dickman CA: Thoracoscopic sympathectomy for hyperhidrosis: analysis of 642 procedures with special attention to Horner's syndrome and compensatory hyperhidrosis. **Neurosurgery** 67:652-656; discussion 656-657, 2010
13. Williams MP, Cherryman GR, Husband JE: Significance of thoracic disc herniation demonstrated by MR imaging. **J Comput Assist Tomogr** 13:211-214, 1989
14. Wood KB, Garvey TA, Gundry C, Heithoff KB: Magnetic resonance imaging of the thoracic spine. Evaluation of asymptomatic individuals. **J Bone Joint Surg Am** 77:1631-1638, 1995